
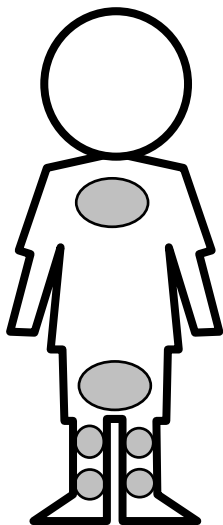


Depiction of Child Abuse Injuries

Location of Typical Abuse-Related Injuries

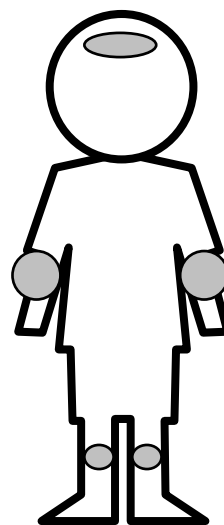


Front View



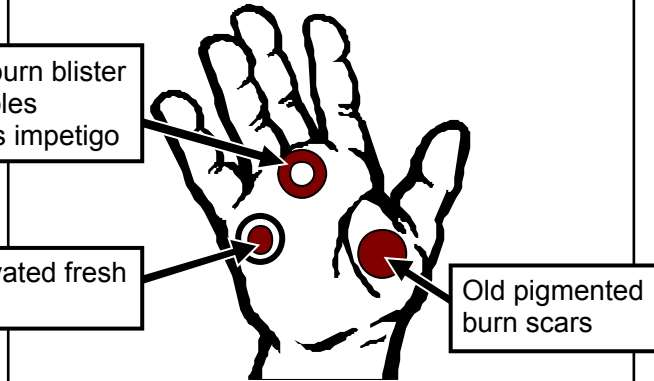



Back View

Location of Typical Accidental Injuries



Front View

Marks from Instruments		Burn Marks	
Belt Buckle		Bite	
Belt		Sauce Pan	
Looped Cord		Paddle	
Lash/Whip		Hair Brush	
Fly Swatter		Spoon	
Coat Hanger		Hot Plate	
Board		Light Bulb	
Hand		Curling Iron	
		Cigarette Lighter	
		Steam Iron	
		Knife	
		Grid	
		Cigarette	
		Fork	
		Immersion	

Apparently Inflicted Burn Injuries	Apparently Inflicted Restraint Injuries
<p>Cigarette burns are usually inflicted on the palms, soles, and buttocks.</p>  <p>Fresh burn blister resembles bulbous impetigo</p> <p>Excavated fresh burn</p> <p>Old pigmented burn scars</p> <p>Burn in various stages of healing indicate repeated abuse</p>	<p>Child may be gagged as punishment or to stop persistent crying.</p> <ul style="list-style-type: none"> Gags leave characteristic bruises at the corners of the mouth. 
<p>Abuse must be suspected if burns are in the configuration of common household utensils or appliances. Abuse should also be suspected if the burn is in an area that is typically covered, or in an unusual area, such as the shoulder.</p>  <p>Back View</p>	 <p>Wrists or ankles may be tied as a form of punishment or to keep child "safe".</p> <ul style="list-style-type: none"> Fresh blister may be caused by rope burns. Hyperpigmented, chronic, rope burn injures leave characteristic scars on the wrists and ankles.